

Original article

A rare clinical presentation of non Hodgkin Lymphoma as multiple neurofibromas with review of literature

Dr.C.R.Sirajunnisa Begum, Professor¹ , Dr. Ira Bharadhwaj, Professor¹ , Dr. Lavanya, Assistant Professor² , Dr. Swaroop N Shashidhar, Assistant Professor¹ , Dr. Hana Abdul Kareem, Assistant Professor¹

¹- Department of Pathology, Karuna Medical College, Vilayodi, Chittur, Kerala, India.

²- Department of Surgery, Karuna Medical College, Vilayodi, Chittur, Kerala, India.

Corresponding author: Dr. Swaroop N Shashidhar, Assistant Professor, Department of Pathology, Karuna Medical College, Vilayodi, Chittur, Kerala, India.

ABSTRACT

An elderly female patient presented with multiple Cutaneous and subcutaneous swellings over both lowerlimbs, left upper limb, face and abdomen of four months duration. On serial imaging (USG and MRI) there was an impression of multiple neurofibromas with sarcomatous change in lesions over right thigh and left face. Biopsy of lesion from right thigh and ankle suggested Non Hodgkin Lymphoma of T cell type. Here in we present a rare clinical presentation of NHL as multiple neurofibromas with sarcomatous change.

INTRODUCTION

The most common presentation (two thirds) of NHL is as lymphadenopathy in an elderly predominantly male patient. In remaining one third, NHL presents at extra nodal sites like skin, stomach or brain¹. There are many different types of NHL which may be broadly classified as B cell or T cell type. Clinically they may be aggressive (fast growing) or indolent (slow growing)^(1,2).

CASE REPORT

An 82 years old lady presented with right ankle ulcer, fatigability. On examination she is pale and has, multiple swellings all over the body, thigh, ankle lower back, wrist, face and paraumbilical regions. Laboratory investigations show – peripheral neutrophilic leukocytosis and raised ESR. All other tests are within normal range. MRI of both lower limbs and face showed multiple neurofibromas in skin/subcutaneous tissue with sarcomatous change of the larger lesion in the posterior aspect of upper one third of right leg and in left side of face overlying left zygoma. No lymphadenopathy detected clinically or on MRI & USG abdomen. The excision biopsy done on right thigh nodule and wedge biopsy from right leg ulceroproliferative area taken and the same sent to the department of pathology. Histopathological examination of both swellings over right thigh and ulcer over right ankle showed similar morphology consists of neoplastic lymphocytic cellular population infiltrating skin, subcutaneous tissue (all the planes) fat and deeper tissue like muscle and surrounding area, reported as Non Hodgkin Lymphoma of T cell type. Immunohistochemistry as follows.

CD3 (T-cell marker ---- positive

CD20 (B-cell marker ---- negative

Ki 67 (Proliferative marker – 85-90% positive

CD23 –negative

CD10 ----- negative

CD4 (Helper – T – cell marker) --- positive

CD 117 ----- negative

CD99 ----- positive

Based on the above IHC markers the cutaneous lesion diagnosed as peripheral T cell Non Hodgkin Lymphoma, unspecified.

Local Examination

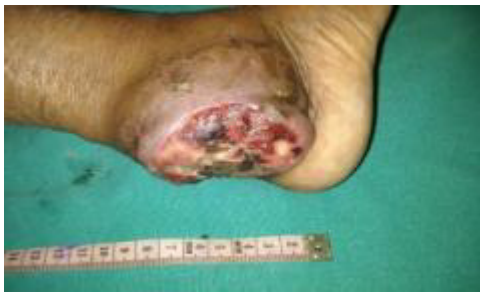

Figure 1: Ulceroproliferative lesion over **ankle**

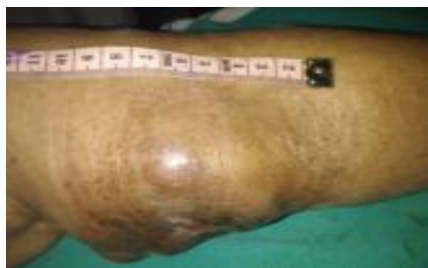

Figure 2: Multiple nodules over **knee**

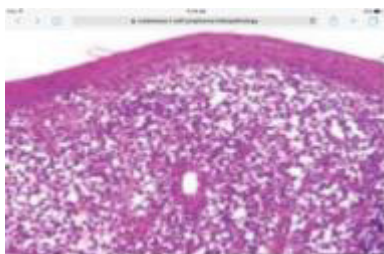


Figure 3: Photomicrography of Cutaneous ulcer

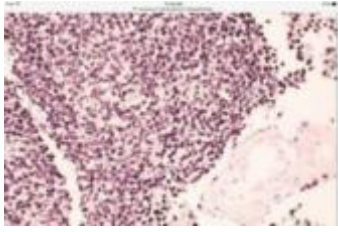


Figure 4: Photomicrography of ulcer showing features of NHL

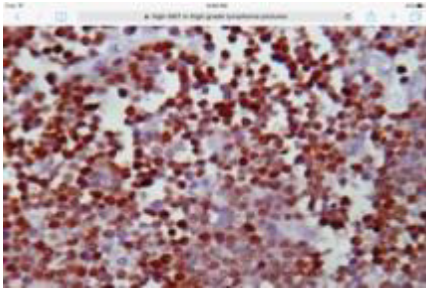


Figure 5: Photomicrography of IHC showing CD20 negativity

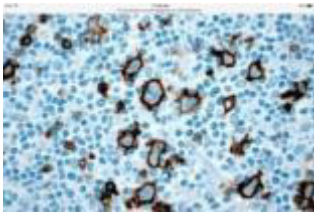


Figure 6: IHC/ ki 67 proliferation




Figure 7: Lcdt negative




Figure 8: CD3 Positive

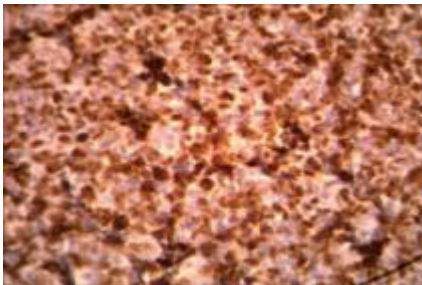


Figure 9: CD99 positive

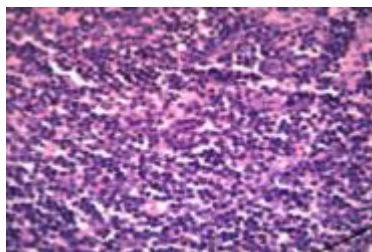


Figure 10: H & E photomicrography

DISCUSSION

NHL may involve the skin as a primary manifestation or as a retrograde lymphatic metastasis from involved lymphnode^[3]. Mature T – cell lymphomas are derived from mature or post thymic T cells. They are relatively uncommon tumours, more common in Asia^[5,8]. Cutaneous T cell lymphoma (CTCL) presents as firm, raised smooth slightly violaceous or erythematous nodules or plaques that range in size from few millimeters to a few centimeters. The nodule may breakdown producing ulcers with sharp borders CTCL may resemble syphilitic gummas or erythema nodosum^[3,4].

CTCL is a neoplastic amplification of skin homing T cells characterized by triad of skin localization, avoidance of bone marrow and infiltration of perifollicular T cell zones of lymphnode and spleen. The serum immunoglobulins are usually normal reflecting the functional capacity of T4 cells to stimulate B lymphocytes to produce immunoglobulin and protect against encapsulated bacteria. The pathogenesis of this cancer is postulated as clonal proliferation of CD4 T cells in response to signals from intra epidermal dendritic antigen presenting langerhans cells via class II MHC

complexes and T cell receptors (TCRS). CTCL may be a malignancy of T cells stimulated to proliferate against its own tumor antigens. The intriguing possibility of a yet undifferentiated transforming retrovirus in dendritic cells which stimulate and transform single clone of Cutaneous T cells should also be considered^[6].

WHO, EORTC classifies Cutaneous lymphomas with primary Cutaneous manifestations as 14 subtypes of T cell and NK cell and 5 subtypes of B- cell. Clinical outcomes based on WHO- EORTC classification divide the Cutaneous T-cell lymphomas as 5 subtypes with indolent behavior and five subtypes with aggressive behavior. The commonest CTCL with indolent behavior is mycosis fungoides and its variants, while Sezary syndrome is the commonest type with aggressive behavior. Primary Cutaneous peripheral T cell lymphoma, unspecified accounts for approximately 2% of CTCL and 3.7 % of all mature T cell lymphoma it is an aggressive tumor with poor survival⁵. The terminology peripheral T cell lymphoma (unspecified) emphasizes that these cases do not belong to any of the better defined categories. Attempts to distinguish between them on morphological basis have met with poor inter and intra observer reproducibility^[5,9].

CONCLUSION

This is indeed a rare presentation of rare tumor of primary cutaneous peripheral T cell lymphoma, unspecified. This group as a whole needs to be studied in greater detail.

ACKNOWLEDGEMENT

All staff and management of Karuna Medical College, Vilayodi, Chittur, Palakkad, Kerala, India.

REFERENCES

1. Chan J K. Tumors of lymphoreticular system. In Fletcher CD editor: Diagnostic Histopathology of Tumours 3rded, Elsevier limited 2010 P-598-9.
2. Rosai J. Lymphnodein :Rosai and Ackermans surgical pathology. 9thed. New Delhi:Elsevier: 2005.P.1931-3.
3. Schwartz RA Cutaneous metastatic disease J Am Acad Dermatol 1995; 33:161-82.
4. Smoller B other Lymphoproliferative and myoproliferative diseases In Bologna JL, editor Dermatology Istedi. Vol.2 Philadelphia: Elsevier's Health sciences: 2003 P, 1943-51
5. Swerdlow SH, Campo E, Harris NL, et al WHO classification of tumours pathology and Genetics :Tumours of Haematopoietic and lymphoid tissues 4thed. Lyon, France IARC Press; 2008.
6. Richard L Edelson (2001) Cutaneous T cell lymphoma. Annals of the New York academy of science, 941:1-11 DOI:10-1111/j.1749-6632.2001.tb03705.
7. Longo DL. Malignancies of lymphoid cells. In:Fauci A S, Kasper DL, Longo DL, Barunwald Harrison's principles of internal medicine. 18thed USA: McGraw-Hill Organization ; 2008 P.692-3.
8. Kumar V Abbas A K, Fauster N, Aster JC. Diseases of WBC, lymph node, spleen and thymus, In: Robbins and cotran Pathologic basis disease. 8th ed. Philadelphia: Elsevier Limited; 2010.p.588-9.
9. Willemze R, Jaffe ES, Burg G, Cerroni L, Berti E, Swerdlow SH, Ralfkiaer E, Chimenti S, Diaz-Perez JL, Duncan LM, Grange F, Harris NL, Kempf W, Kerl H, Kurrer M, Knobler R, Pimpinelli N, Sander C, Santucci M, Sterry W, Vermeer MH, Wechsler J, Whittaker S, Meijer CJ, (2005). WHO –EORTC classification for Cutaneous lymphomas, Blood 105:3768-3785.